

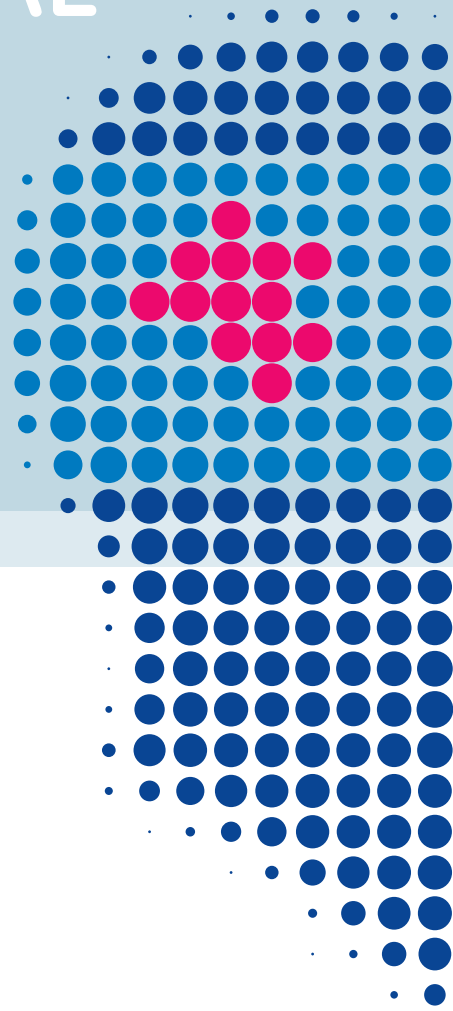
Gliolan[®]

TRAINING MANUAL

Guidance for health professionals on reducing handling errors and other risks for Gliolan[®]

Version 3 - November 2024

Marketing Authorisation Holder in the EU/EEA: photonamic GmbH & Co. KG







Table of contents

Introduction	4
What is the current understanding of the benefits and risks of cytoreductive surgery in the management of patients with malignant gliomas?	4
What are the technical principles behind fluorescence-guided resections using Gliolan®?	5
Who are suitable candidates for fluorescence-guided resection using Gliolan®?	6
How to apply Gliolan® in the correct dose and time regimen	7
Which aspects have to be considered regarding light protection?	9
Which aspects have to be considered regarding intra-operative photosensitisation of normal brain tissue?	10
Which equipment is required?	10
Which techniques can be used for intraoperative risk reduction?	11
Does photobleaching of porphyrins destroy tissue fluorescence and impair sensitivity?	12
How far to resect	13
How to identify patients at risk for neurological deficits when using fluorescence-guided resection	13
What is the benefit-risk balance for the use of Gliolan®?	17

Abbreviations

ALA	5-aminolevulinic acid
AUC	Area under the curve
CNS	Central nervous system
Fig.	Figure
MR(I)	Magnetic resonance imaging
PpIX	Protoporphyrin IX



Introduction

Glioblastoma represents the most frequent malignant brain tumour in adults. The disease often progresses rapidly over 2 to 3 months and is incurable. Median overall survival is approximately one year. In spite of the incurability of the disease, quality and prolongation of the patient's life can usually be increased by surgery. The main aim of surgery is the safe removal of all contrast-enhancing tumour areas. In the past, this was viewed to be a major factor in determining progression and ultimately, survival¹⁻⁴. Furthermore, emerging novel adjuvant therapies, such as immune therapy, gene therapy or strategies for chemotherapy, will most likely rely on maximum cytoreduction to be as effective as possible. However, the removal of the tumour is complicated even for experienced neurosurgeons due to its location and the fact that infiltrating, marginal tumour is difficult to distinguish from brain. Optical markers for detection of the tumour aim to improve the results of the cancer surgery.

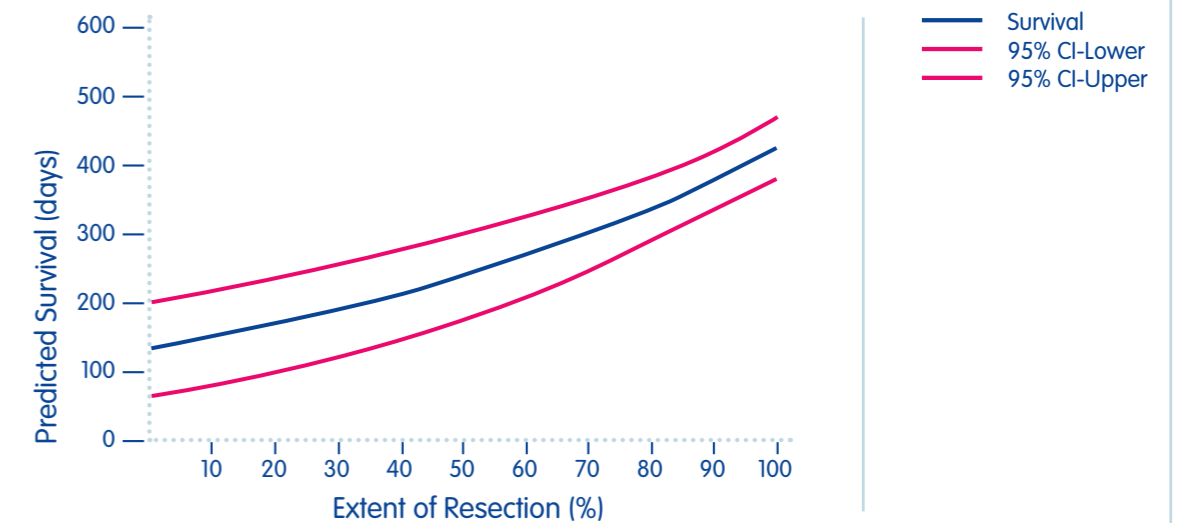
What is the current understanding of the benefits and risks of cytoreductive surgery in the management of patients with malignant gliomas?

The goals of surgery are to obtain a diagnosis, alleviate symptoms related to increased intracranial pressure or compression by tumour, increase survival, and decrease the need for corticosteroids⁵. Clinical trials have repeatedly demonstrated survival of patients to be associated with the degree of tumour resection, and the best prognosis to be associated with complete resection of contrast-enhancing tumour^{2, 6-13}. This applies also to elderly patients¹⁴.

Unfortunately, nearly all high-grade gliomas recur. Likewise, in the case of recurrence/re-operation, gross total resection has proven beneficial in these patients^{16, 17}. Finally, complete resections appear to improve the efficacy of adjuvant therapies¹².

Tumour areas located adjacent to critical/eloquent brain areas bear the risk of a possible neurological defect induced by resection. Current treatment guidelines for glioma patients recommend maximum surgical resection, while preserving neurological function^{5, 18-20}.

Fig. 1: Extent of resection and survival¹⁵



What are the technical principles behind fluorescence-guided resections using Gliolan®?

5-aminolevulinic acid (ALA) is a medicinal product which serves as a metabolic marker of malignant glioma cells due to specific differences in its cellular metabolism that can be used intraoperatively for identifying residual tumour. ALA is the body's own metabolite in the heme biosynthesis pathway (**Fig. 2**). Experimental and clinical studies have shown ALA to be taken up by malignant glioma cells, where it is converted into strongly fluorescing porphyrins, particularly protoporphyrin IX (PpIX)²¹.

Exogenous administration of ALA results in increased production and accumulation of PpIX in tumour tissues of epithelial and mesenchymal origin. In the brain, ALA enters malignant gliomas through the leaky blood-brain barrier. When illuminated with violet-blue light, tumour tissue can be distinguished from normal-appearing tissue by red fluorescence even though differences are not evident using conventional white light illumination. Using specifically modified surgical microscopes, the resulting fluorescence of malignant glioma tissue can be utilised for resecting these tumours^{3, 22}.


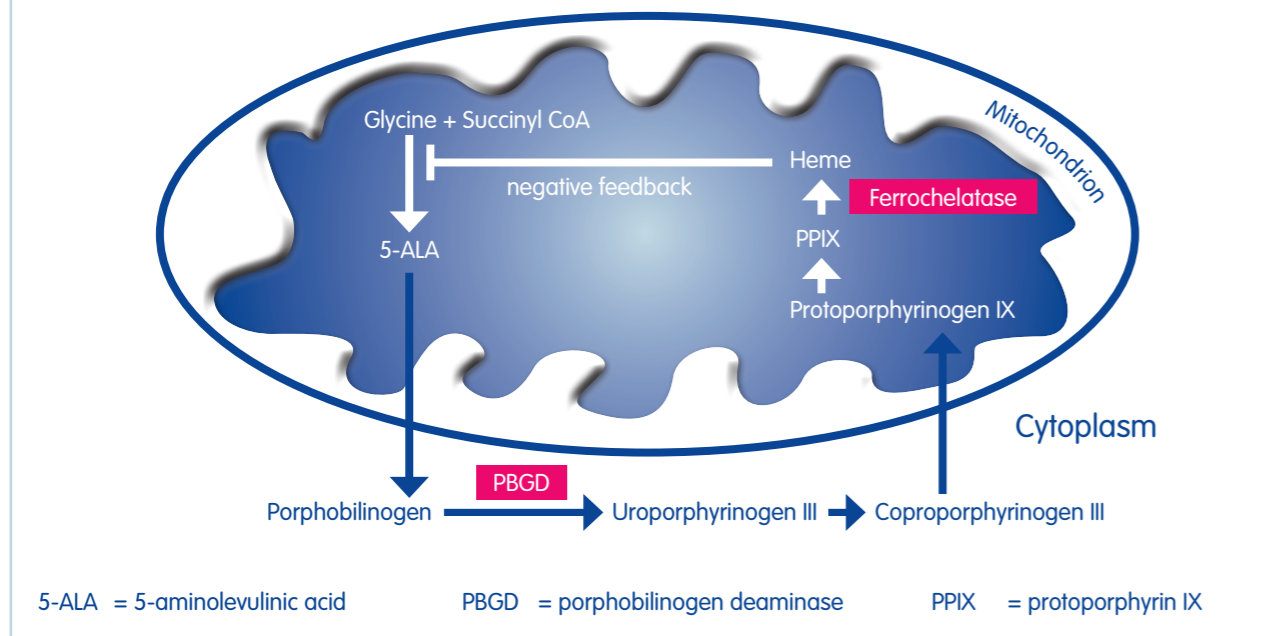


Fig. 2: Heme biosynthesis pathway. Accumulation of PpIX following external 5-ALA administration



Who are suitable candidates for fluorescence-guided resection using Gliolan®?

Suitable candidates for fluorescence-guided resection using Gliolan® are patients with malignant gliomas or patients in whom malignant gliomas are strongly suspected. Intra-operative frozen sections are strongly recommended to confirm malignant glioma histology, as non-glial tumour entities and inflammation (fungal or bacterial infections or abscesses, metastasis, CNS lymphoma, vasculitis, radiation necrosis, abnormal brain tissue with reactive astrocytes or atypical cells and others) can accumulate PpIX. Some of these conditions (e.g. abscess, metastasis) have similar imaging features as malignant gliomas²³.

In principle, any patient with a suspected malignant glioma for whom debulking surgery is indicated might benefit from information that fluorescence gives to surgeons. However, fluorescence is only one of many technical adjuncts to surgery, and resection relies on numerous factors that are part of neurosurgical training and experience. Thus, only general comments can be given here.

Fluorescence does not reduce the necessity for using mapping and monitoring techniques in patients at risk because tumours are associated with important brain structures.

In patients undergoing subtotal resection with minimal residual disease, tumour fluorescence can allow the surgeon to specifically identify and minimise residual tumour in critical areas.

Apart from identifying residual disease, fluorescence can help when approaching deep-seated tumours or for defining a surgical strategy when diseased tissue is identified early during surgery.

Gliolan® should not be used as a tool for establishing the diagnosis of high-grade glioma, but is used as an aid to perform maximum safe resection. Some cases of fluorescence in conditions other than gliomas have been reported. The differential diagnosis for lesions showing fluorescence, when surgery for a suspected high-grade glioma was performed, include: inflammation, fungal or bacterial infection/abscess, necrotic tissue, multiple sclerosis, and neurodegenerative demyelinating disease²³.


How to apply Gliolan® in the correct dose and time regimen

What is the rationale behind the Gliolan® treatment regimen?

Fluorescence-guided resections using ALA are performed using an oral dose of 20 mg ALA/kg bodyweight. Dexamethasone is given as clinically indicated, with a usually recommended dose of 3 x 4 mg per day for 2 days in preparation for surgery. In the pivotal trial for Gliolan®, dexamethasone had not been administered in the morning prior to Gliolan® and for three hours thereafter. This regimen has proven efficient and might be advisable to rule out any theoretical interaction of dexamethasone and the blood-brain barrier, possibly impairing ALA uptake.

Lower doses of Gliolan® (0.2 and 2 mg/kg) have been tested but found to generate considerably less fluorescence and were thus abandoned²⁴. That same study revealed no differences in the frequency of adverse and severe adverse events between the three doses.

Higher doses of up to 50 mg/kg bodyweight have been tested in a dose escalation study; no increase in adverse events of grade 2 or higher was found and dose-limiting toxicity was not reached²⁵. However, systemic side effects with higher doses of ALA, as used in other indications, have been reported²⁶⁻²⁹. Furthermore, the accumulation of PpIX is limited, e.g. 10 x ALA leads to only 3 x overall PpIX content (area under the curve [AUC]) and 1.6 x max. peak PpIX. Other factors, e.g. illumination intensity, play a comparable or larger role than PpIX content.



At what time is Gliolan® given?

ALA is given to patients orally 2 to 4 hours before the induction of anaesthesia.

For surgery on patients it was calculated that induction of anaesthesia, positioning of the patient, draping, and craniotomy would take approximately 1.5 to 2 hours. Allowing another hour for removal of the clearly discernible tumour core, surgeons would be 3 to 3.5 hours into the operation before fluorescence guidance becomes necessary. A recent publication found that the maximum PpIX plasma level is reached 7 – 8 hours after oral administration of 20 mg/kg body weight ALA³⁰. This suggests that it would be beneficial to give the medicinal product early rather than late within the prescribed time range. At the recommended oral dose of 20 mg/kg body weight, tumour to normal brain fluorescence ratios are usually high and offer lucid contrast for visual perception of tumour tissue under violet-blue light for at least 9 hours.

PpIX plasma levels rapidly decline during the subsequent 20 hours and are not detectable anymore 48 hours after administration.

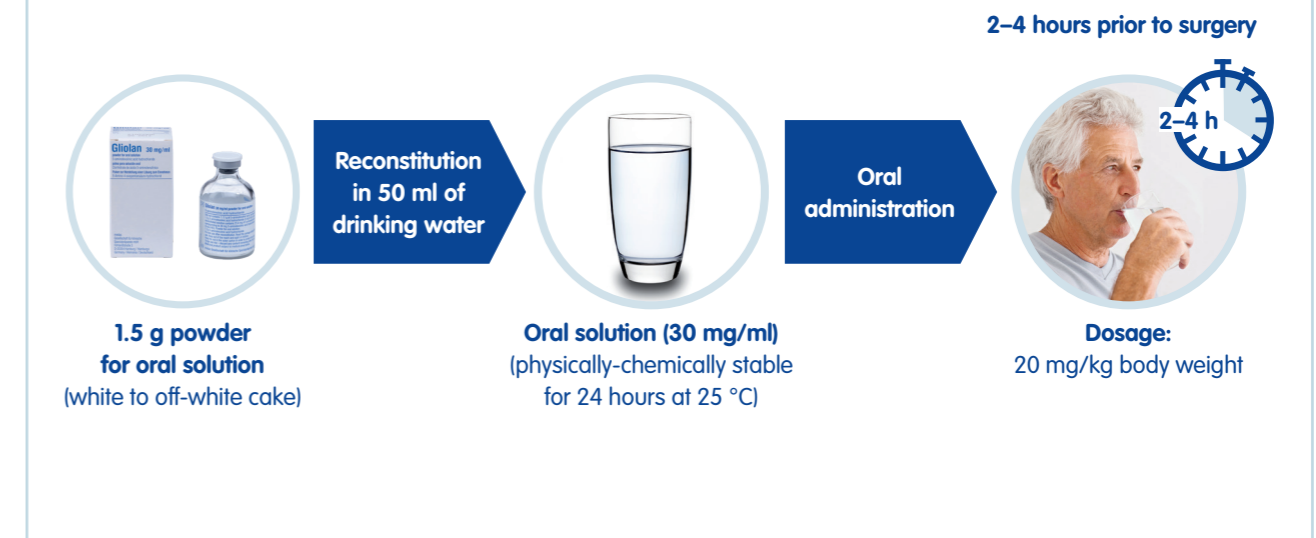
Occasionally, delays and postponement of surgery may occur despite ALA having been administered. It is basically unknown for how long useful fluorescence persists in tumour cells beyond the defined window of lucid contrast. If the surgery is delayed by more than 12 hours, surgery should be re-scheduled for the next day or later and ALA should be re-administered. Re-administration of ALA on the same day should be avoided as no data are available on the safety of a repeated dose of ALA or the specificity of fluorescence with repeat same day administration.

How is Gliolan® administered?

Prior to administration, the compound is easily dissolved in tap water and should be freshly prepared to rule out degradation (**Fig. 3**).

Pharmacokinetic assessments have demonstrated complete absorption of the total ALA-dose within 1 hour of oral administration, so that the solution can be expected to have passed the intestine at the time when anaesthesia is induced.


Fig. 3: Administration of ALA



Which aspects have to be considered regarding light protection?

Sensitisation of the skin has been reported after systemic application of ALA with a peak at 6-8 hours and a duration of approximately 24 hours^{27-29, 31, 32}. Consequently, direct exposure of patients to sunlight or strong room light has to be avoided for 24 hours. Low levels of ambient light are permitted during the post-operative period. Between the time of ALA administration and induction of anaesthesia, low levels of ambient light are permitted.

During the preparations for surgery the direct illumination of patients' undraped skin with operating lights should be avoided. The largest risk may be in patients in whom surgery is postponed, who are left in the hospital ward bed, and who are at risk of being exposed to outside light. Restrictions regarding light exposure are maintained for 24 hours after ALA administration.



Which aspects have to be considered regarding intraoperative photosensitisation of normal brain tissue?


Spectrographic studies have confirmed that with 20 mg/kg Gliolan® treatment in patients pre-treated with steroids, no ALA-dependent porphyrin fluorescence is detectable within normal or oedematous, perifocal human brain. Experimental results did not show any risk of damage to healthy brain tissue during fluorescence-guided neurosurgery by phototoxic mechanisms as the amount of light needed to cause phototoxic damage is much higher than that emitted by the surgical microscope^{13, 33}.

Which equipment is required?

Fluorescence-guided resections using Gliolan® are approved for use with specifically modified surgical microscopes.

Fluorescence imaging hardware has to be adapted to the microscope. The microscope features a specific combination of excitation and emission filters with slightly overlapping transmission²². Due to the overlap, a small fraction of the excitation light is remitted from tissue, which gives normal brain a blue tone in contrast to bright red porphyrin fluorescence. The degree of filter overlap is crucial for successful imaging. If the remitted light is too strong, porphyrin fluorescence is no longer recognisable. If the remitted light is too weak, surgery becomes difficult due to the lack of tissue detail. Also, faint autofluorescence in the red spectral region becomes visible and can be mistaken for porphyrin fluorescence. Finally, in order to visualise fluorescence on a video screen for documentation purposes, specially modified video cameras are needed. During surgery, the impression directly obtained with the eye should be relied upon as it has the greatest range of perceiving differences in fluorescence intensity and distinguishing fluorescing from non-fluorescing tissue. With the camera system it is possible to increase gain and integration arbitrarily in order for fluorescence to appear more intense. However, unaffected brain tissue has a slight red autofluorescence, which is not perceived under normal conditions or with the eye. Undoing amplification of the camera signal will cause normal tissue to appear vaguely fluorescent (**Fig. 4**).


Fig. 4: Overamplification or overintegration of video signal generated during fluorescence-guided resection. Blue, inconspicuous neighbouring tissue adapts red fluorescence which represents overamplified autofluorescence and not porphyrin fluorescence (left: normal video view, right: overamplified image).




Which techniques can be used for intraoperative risk reduction?

Precautions regarding light exposure should be followed. Neuronavigation can be a useful adjunct for planning craniotomy or locating tumours which do not reach the cortical surface. Alternatively, sonography may be used for the initial localisation of tumour. At times, even when the cortical surface appears inconspicuous, switching to blue excitation light may allow discrimination of subcortical tumour extensions, providing a valuable guide for initial corticotomy (**Fig. 5**). In deep-seated tumours, the correct trajectory can sometimes be verified by fluorescence in infiltrating extensions of the tumour.

Fig. 5: Tumour fluorescence shining through cortex allowing precise planning of initial corticotomy for reaching the tumour





If surgery is performed within eloquent brain regions, methods should be employed for minimising the risks of neurological deficits such as intraoperative stimulation, awake craniotomies, or careful evaluation of functions (speech, motor) using functional magnetic resonance imaging (MRI), or mapping of fibre tracts using tractography. Sonography can be helpful in defining gross anatomy, for instance when operating on temporal tumours extending toward the basal ganglia.

There are different methods for operating on a malignant glioma. Surgeons might prefer to remove necrotic and easily distinguishable solid tumour regions first, predominantly under white light, and then to remove marginal, residual tumour using fluorescence-guided resection. Alternatively, they might choose to remain in fluorescing tumour margins at the resection plane. Simple suction or the ultrasound aspirator can be used for removing tumour. Electrocautery will destroy superficial fluorescence. By sucking away non-fluorescent tissue debris, vital fluorescing tissue is re-exposed which may then be resected. Blood in the resection cavity quenches the fluorescence signal but can easily be removed by suction to give an impression of the fluorescence quality of the tissue. Conditions do not have to be optimised for demonstrating fluorescence. Rather, switching from normal to blue excitation light in the microscope is repeatedly performed manually during the course of the operation. Toward the end, longer periods of the operation can be performed using blue excitation light alone. If unspecific oozing gets too strong and impairs fluorescence detection, white light illumination with its greater detail is used for coagulating vessels.

Does photobleaching of porphyrins destroy tissue fluorescence and impair sensitivity?

Under operating light conditions, fluorescence decayed to 36 % in 25 minutes for violet-blue, and 87 minutes for white light³⁴. During surgery, microscope light is usually directed at a small region of the resection cavity, whereas other areas are often covered by coagulated blood or cotton patties. Still, mild fluorescence may be bleached in exposed regions of the tumour which are not removed immediately and may be missed. In this situation fluorescence may be refreshed by suction and removal of superficial cell layers. Prolonged illumination under white light may occur for instance when waiting for a frozen section.

How far to resect


Past investigations have demonstrated the extent to which ALA-derived fluorescence accumulation exceeds the area of contrast-enhancement observed on MRI¹³. ALA-derived fluorescence appears to be more sensitive in delineating residual tumour. Studies have further demonstrated sensitivity to be limited to a density of infiltrating tumour cells of about 10 %³⁵. Infiltrated brain tissue in these regions might be functionally deficient, however this cannot be assumed in general. Furthermore, disruption of the blood-brain barrier regarding small molecules is a prerequisite for ALA uptake into the brain. Disruption will also preclude a normal milieu interior with intact function. On the other hand, uncritically going beyond this region might lead to neurological deficits. It is also evident that tissue manipulation, such as coagulation or shearing, might result in damage to neighbouring brain regions, with consequent neurological deficits. Furthermore, blood vessels supplying adjacent, eloquent brain regions might be damaged, leading to distant ischaemia, again resulting in neurological deficits.

It is the responsibility of the surgeons to decide how far they are prepared to remove fluorescing tissue. ALA should not replace a critical awareness of cerebral anatomy, vascular supply and function of the brain region in which resections are performed.

How to identify patients at risk for neurological deficits when using fluorescence-guided resection

In the pivotal trial of Gliolan® it was observed that severe deficits concerning language or motor functions were observed in patients in whom pre-existing neurological language or motor deficits did not resolve in response to steroid pre-treatment¹³. However, methods for mapping and monitoring were not used in these patients.

Patients without resolution of critical functions after steroid pre-treatment should not be operated on using fluorescence-guided resections, or, if the eloquent brain region at risk can be identified (either by preoperative functional imaging or intraoperative mapping techniques), critical areas should be left unresected.

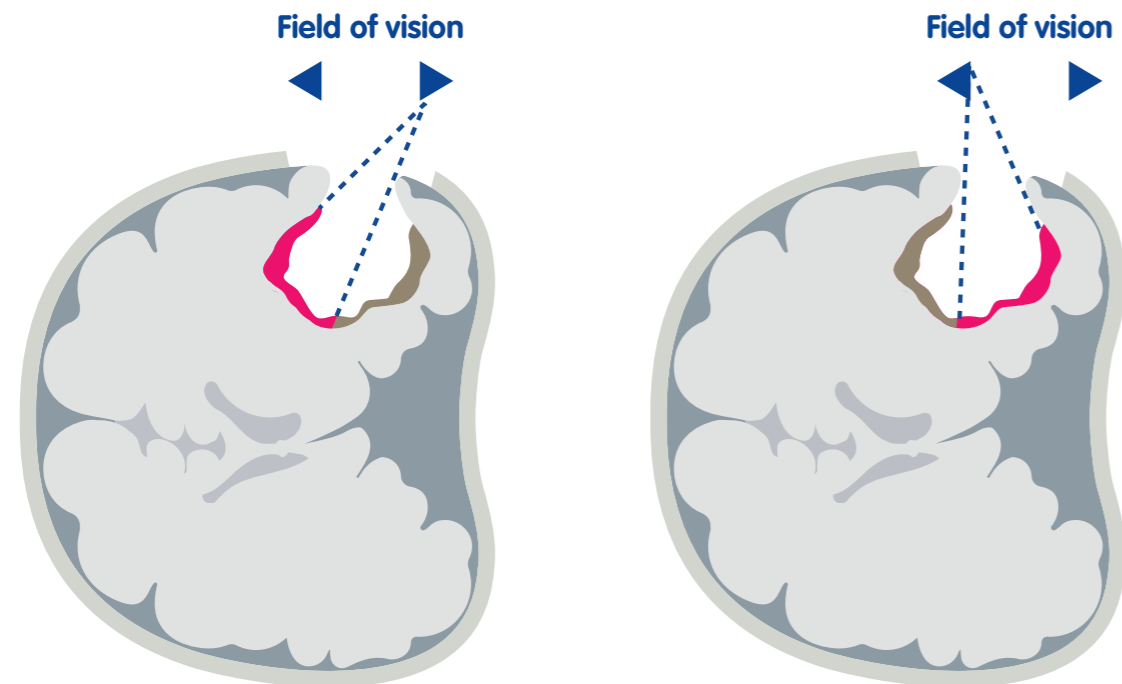


Even if eloquent areas are not directly affected but close to contrast-enhancing tumour, all measures for risk reduction should be implemented, such as intraoperative monitoring or mapping techniques and careful preoperative planning.

PITFALLS


1. In some studies on fluorescence-guided resections using ALA, incompletely resected tumours were observed in which anatomical location did not preclude complete resection. An analysis of the images pertaining to these patients revealed a common problem, the problem of overhanging margins (**Fig. 6**). During resection, surgeons tend to undercut the cortex, leaving residual tumour under the margins; that is, outside the surgeon's direct field of vision.

Fig. 6: Overhanging edges may obscure line of vision to residual tumour




2. A second problem can frequently be encountered in tumours with cystic portions and slender margins of enhancement. Opening the cysts leads to the collapse of parts of the tumour, which in some cases might be missed (**Fig. 7**).

Fig. 7: Cysts that collapse



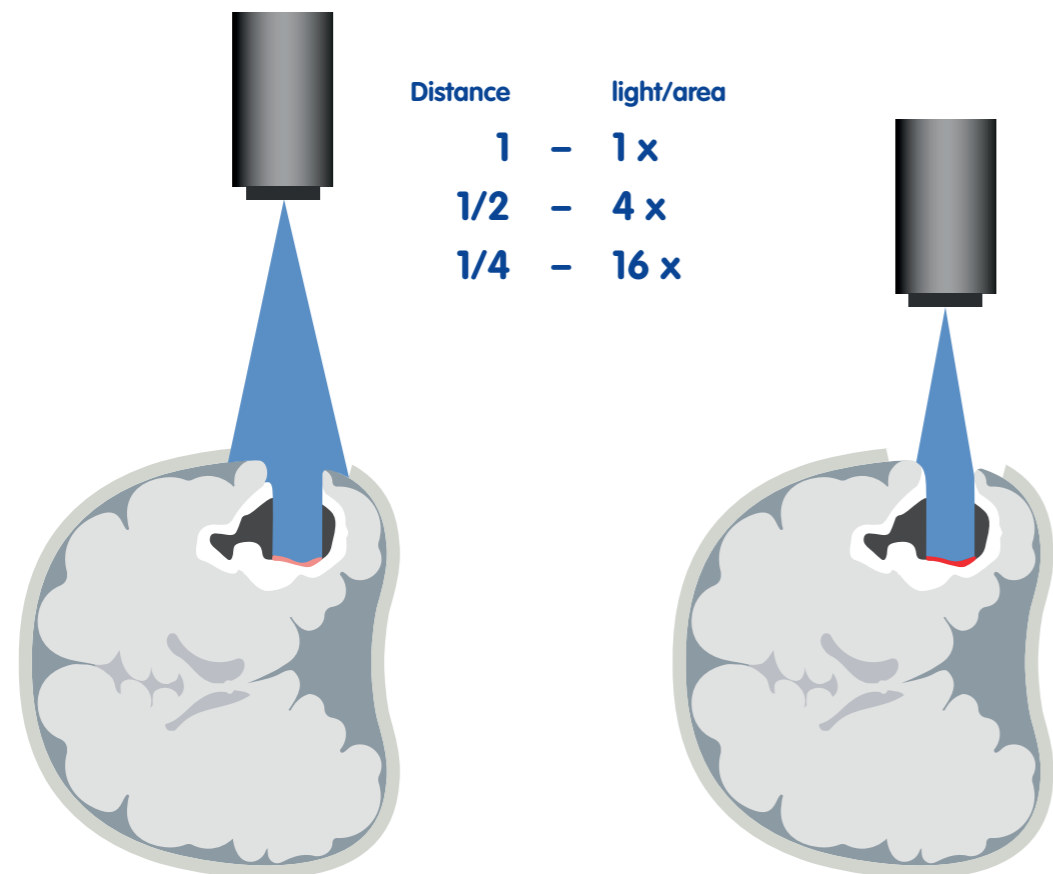
3. Wrongly placed craniotomies have been identified as the main factor for precluding complete resection of contrast-enhancing tumour.

4. Other pitfalls were observed when patients' histology did not conform to the expected malignant glioma; for example, when they suffered abscess, metastasis, vasculitis, and lymphoma³⁶. Both abscesses and metastases are sometimes surrounded by a region with weak, unspecific fluorescence accumulation. Patients with lymphoma and necrotizing vasculitis were also observed to demonstrate strong fluorescence accumulation within their lesions, possibly related to inflammatory or neoplastic cells. Obtaining frozen sections at an early stage of the procedure in any unclear cases is recommended to prevent unnecessary resection in non-surgical lesions. Similarly, stereotactic biopsy might be performed ahead of definite surgery to clarify diagnosis in ambiguous MR images.



5. Some cases of gliosarcoma have been observed to show modest fluorescence accumulation within those areas of the tumour with predominantly solid texture, although infiltrating tumour beyond that had revealed the expected fluorescence.
6. Too weak fluorescence has been related to overaged xenon lamps. The system should be tested carefully prior to the draping of the microscope, in order to identify malfunction early and to prevent undue delays during the procedure.
7. Illumination geometry plays a role. There is an exponential decline of excitation light intensity with growing distance, thus distance should be kept small, if feasible. If resection is performed through a small corticotomy, the light reaching into the cavity may be limited (**Fig. 8**).

Fig. 8: Exponential decrease in light with growing distance to fluorescent tissue, resulting in weak fluorescence intensity. Furthermore, small corticotomies shade illumination light and also result in low fluorescence intensities.



With ongoing resection the fluorescence signal appears to increase; this is probably related to progressive widening of the approach corridor within the cortex. Positioning of the microscope so that the illumination light is as perpendicular to the resection surface as possible will increase fluorescence yields.

8. Finally, ambient light within the operating room will interfere with the fluorescence signal. Neon lighting contains substantial red and infrared light. Red wavelengths are selectively amplified by the detection equipment and thus lead to red discoloration of non-tumour tissue normally perceived as being blue. This problem is recognised when the normal cortical surface displays a general reddish tone. Standard surgical lights are usually filtered in the red and infrared wavelengths. During the procedure, it is recommended to switch off all neon illumination, whereas surgical lights are directed away from the surgical cavity toward the instrument trays. The operating rooms have to be darkened with respect to daylight.


What is the benefit-risk balance for the use of Gliolan®?

There is no doubt that the use of fluorescence-guidance after oral administration of ALA increases tumour visualisation and the rate of radiological complete tumour resection as has been convincingly shown in study MC-ALS.3/GLI¹³.

Additionally, within this study it was demonstrated for the first time in a large prospectively randomised (before surgery) phase III clinical trial that this more aggressive tumour debulking leads to a significant benefit with respect to the progression-free survival rate¹³.

Compared to the control group, approximately twice as many patients in the experimental group were progression-free at 6 months. Supplemental time to event analyses with tumour progression defined according to the Macdonald criteria clearly show that this increase in progression-free survival in the experimental arm is not counterbalanced by worsened neurological findings¹³. Nowadays with increased experience, the method has been established and more evidence on the impact of ALA on the extent of resection and survival for glioma patients has been found^{37, 38}.

More recently, awareness has increased that mapping and monitoring techniques are of value for maximising safe resections in glioma surgery³⁹. While the proficiency of ALA for finding residual tissue has remained the same, employing mapping and monitoring techniques will further help increase the safety of this method.



Literature cited

1. Devaux BC, O'Fallon JR, Kelly PJ. Resection, biopsy, and survival in malignant glial neoplasms. A retrospective study of clinical parameters, therapy, and outcome. *J Neurosurg* 1993; 78(5):767–75.
2. Lacroix M, Abi-Said D, Fourney DR, Gokaslan ZL, Shi W, DeMonte F et al. A multivariate analysis of 416 patients with glioblastoma multiforme: prognosis, extent of resection, and survival. *J Neurosurg* 2001; 95(2):190–8.
3. Stummer W, Novotny A, Stepp H, Goetz C, Bise K, Reulen HJ. Fluorescence-guided resection of glioblastoma multiforme by using 5-aminolevulinic acid-induced porphyrins: a prospective study in 52 consecutive patients. *J Neurosurg* 2000; 93(6):1003–13.
4. Albert FK, Forsting M, Sartor K, Adams HP, Kunze S. Early postoperative magnetic resonance imaging after resection of malignant glioma: objective evaluation of residual tumor and its influence on regrowth and prognosis. *Neurosurgery* 1994; 34(1):45–60; discussion 60–1.
5. Nabors LB, Portnow J, Ahluwalia M, Baehring J, Brem H, Brem S et al. Central Nervous System Cancers, Version 3.2020, NCCN Clinical Practice Guidelines in Oncology. *J Natl Compr Canc Netw* 2020; 18(11):1537–70.
6. Ushio Y, Kochi M, Hamada J, Kai Y, Nakamura H. Effect of surgical removal on survival and quality of life in patients with supratentorial glioblastoma. *Neurol Med Chir (Tokyo)* 2005; 45(9):454–60; discussion 460–1.
7. Tang S, Liao J, Long Y. Comparative assessment of the efficacy of gross total versus subtotal total resection in patients with glioma: A meta-analysis. *Int J Surg* 2019; 63:90–7.
8. Stummer W, Reulen H-J, Meinel T, Pichlmeier U, Schumacher W, Tonn J-C et al. Extent of resection and survival in glioblastoma multiforme: identification of and adjustment for bias. *Neurosurgery* 2008; 62(3):564–76; discussion 564–76.
9. Bricolo A, Turazzi S, Cristofori L, Gerosa M, Grosslercher JC, Talacchi A et al. Experience in „radical“ surgery of supratentorial gliomas in adults. *J Neurosurg Sci* 1990; 34(3–4):297–8.
10. Obwegeser A, Ortler M, Seiwald M, Ulmer H, Kostron H. Therapy of glioblastoma multiforme: a cumulative experience of 10 years. *Acta Neurochir (Wien)* 1995; 137(1–2):29–33.
11. Li X-Z, Li Y-B, Cao Y, Li P-L, Liang B, Sun J-D et al. Prognostic implications of resection extent for patients with glioblastoma multiforme: a meta-analysis. *J Neurosurg Sci* 2017; 61(6):631–9.
12. Van den Bent MJ, Stupp R, Mason W, et al. Impact of the extent of resection on overall survival in newly-diagnosed glioblastoma after chemoradiation with temozolamide: further analysis of EORTC study 26981. In: *Eur J Cancer Suppl.* p. 134.
13. Final Study Report MC-ALS.3/GLI. medac; 2006.
14. Almenawer SA, Badhiwala JH, Alhazzani W, Greenspoon J, Farrokhyar F, Yarascavitch B et al. Biopsy versus partial versus gross total resection in older patients with high-grade glioma: a systematic review and meta-analysis. *Neuro Oncol* 2015; 17(6):868–81.
15. Marko NF, Weil RJ, Schroeder JL, Lang FF, Suki D, Sawaya RE. Extent of resection of glioblastoma revisited: personalized survival modeling facilitates more accurate survival prediction and supports a maximum-safe-resection approach to surgery. *J Clin Oncol* 2014; 32(8):774–82.
16. Suchorska B, Weller M, Tabatabai G, Senft C, Hau P, Sabel MC et al. Complete resection of contrast-enhancing tumor volume is associated with improved survival in recurrent glioblastoma—results from the DIRECTOR trial. *Neuro Oncol* 2016; 18(4):549–56.
17. Lu VM, Goyal A, Graffeo CS, Perry A, Burns TC, Parney IF et al. Survival Benefit of Maximal Resection for Glioblastoma Reoperation in the Temozolomide Era: A Meta-Analysis. *World Neurosurg* 2019; 127:31–7.
18. Weller M, van den Bent M, Preusser M, Le Rhun E, Tonn JC, Minniti G et al. EANO guidelines on the diagnosis and treatment of diffuse gliomas of adulthood. *Nat Rev Clin Oncol* 2021; 18(3):170–86.
19. Sulman EP, Ismaila N, Chang SM. Radiation Therapy for Glioblastoma: American Society of Clinical Oncology Clinical Practice Guideline Endorsement of the American Society for Radiation Oncology Guideline. *J Oncol Pract* 2017; 13(2):123–7.
20. Farrell C, Shi W, Bodman A, Olson JJ. Congress of neurological surgeons systematic review and evidence-based guidelines update on the role of emerging developments in the management of newly diagnosed glioblastoma. *J Neurooncol* 2020; 150(2):269–359.
21. Stummer W, Stocker S, Novotny A, Heimann A, Sauer O, Kempfski O et al. In vitro and in vivo porphyrin accumulation by C6 glioma cells after exposure to 5-aminolevulinic acid. *Journal of Photochemistry and Photobiology B: Biology* 1998; 45(2–3):160–9.
22. Stummer W, Stepp H, Möller G, Ehrhardt A, Leonhard M, Reulen HJ. Technical principles for protoporphyrin-IX-fluorescence guided microsurgical resection of malignant glioma tissue. *Acta Neurochir (Wien)* 1998; 140(10):995–1000.
23. La Rocca G, Sabatino G, Menna G, Altieri R, Ius T, Marchese E et al. 5-Aminolevulinic Acid False Positives in Cerebral Neuro-Oncology: Not All That Is Fluorescent Is Tumor. A Case-Based Update and Literature Review. *World Neurosurg* 2020; 137:187–93.
24. Final study report MC-ALS.8-I/GLI. Clinical phase I/II study on 5-aminolevulinic acid hydrochloride (5-ALA) for fluorescence-guided resection of malignant gliomas.; 2005 2005 Jun 9.
25. Cozzens JW, Lokaitis BC, Moore BE, Amin DV, Espinosa JA, MacGregor M et al. A Phase I Dose-Escalation Study of Oral 5-Aminolevulinic Acid in Adult Patients Undergoing Resection of a Newly Diagnosed or Recurrent High-Grade Glioma. *Neurosurgery* 2017; 81(1):46–55.
26. Herman MA, Webber J, Fromm D, Kessel D. Hemodynamic effects of 5-aminolevulinic acid in humans. *Journal of Photochemistry and Photobiology B: Biology* 1998; 43(1):61–5.
27. Fan KFM, Hopper C, Speight PM, Buonaccorsi G, MacRobert AJ, Bown SG. Photodynamic therapy using 5-aminolevulinic acid for premalignant and malignant lesions of the oral cavity. *Cancer* 1996; 78(7):1374–83.
28. Regula J, MacRobert AJ, Gorchein A, Buonaccorsi GA, Thorpe SM, Spencer GM et al. Photosensitisation and photodynamic therapy of oesophageal, duodenal, and colorectal tumours using 5 aminolaevulinic acid induced protoporphyrin IX—a pilot study. *Gut* 1995; 36(1):67–75.
29. Mlky P, Messmann H, Regula J, Conio M, Pauer M, Millson CE et al. Sensitization and photodynamic therapy (PDT) of gastrointestinal tumors with 5-aminolaevulinic acid (ALA) induced protoporphyrin IX (PPIX). A pilot study. *Neoplasma* 1995; 42(3):109–13.
30. Kaneko S, Suero Molina E, Ewelt C, Warneke N, Stummer W. Fluorescence-Based Measurement of Real-Time Kinetics of Protoporphyrin IX After 5-Aminolevulinic Acid Administration in Human In Situ Malignant Gliomas. *Neurosurgery* 2019; 85(4):E739–E746.
31. Ackroyd R, Brown N, Vernon D, Roberts D, Stephenson T, Marcus S et al. 5-Aminolevulinic acid photosensitization of dysplastic Barrett's esophagus: a pharmacokinetic study. *Photochem Photobiol* 1999; 70(4):656–62.
32. Tope WD, Ross EV, Kollias N, Martin A, Gillies R, Anderson RR. Protoporphyrin IX Fluorescence Induced in Basal Cell Carcinoma by Oral δ-Aminolevulinic Acid. *Photochem Photobiol* 1998; 67(2):249.
33. Stummer W, Pichlmeier U, Meinel T, Wiestler OD, Zanella F, Reulen H-J. Fluorescence-guided surgery with 5-aminolevulinic acid for resection of malignant glioma: a randomised controlled multicentre phase III trial. *The Lancet Oncology* 2006; 7(5):392–401.
34. Stummer W, Stocker S, Wagner S, Stepp H, Fritsch C, Goetz C et al. Intraoperative detection of malignant gliomas by 5-aminolevulinic acid-induced porphyrin fluorescence. *Neurosurgery* 1998; 42(3):518–25; discussion 525–6.
35. Stummer W, Tonn J-C, Goetz C, Ullrich W, Stepp H, Bink A et al. 5-Aminolevulinic acid-derived tumor fluorescence: the diagnostic accuracy of visible fluorescence qualities as corroborated by spectrometry and histology and postoperative imaging. *Neurosurgery* 2014; 74(3):310–9; discussion 319–20.
36. Tonn J-C, Stummer W. Fluorescence-guided resection of malignant gliomas using 5-aminolevulinic acid: practical use, risks, and pitfalls. *Clin Neurosurg* 2008; 55:20–6.
37. Hadjipanayis CG, Widhalm G, Stummer W. What is the Surgical Benefit of Utilizing 5-Aminolevulinic Acid for Fluorescence-Guided Surgery of Malignant Gliomas? *Neurosurgery* 2015; 77(5):663–73.
38. Lakomkin N, Hadjipanayis CG. Fluorescence-guided surgery for high-grade gliomas. *J Surg Oncol* 2018; 118(2):356–61.
39. Witt Hamer PC de, Robles SG, Zwinderman AH, Duffau H, Berger MS. Impact of intraoperative stimulation brain mapping on glioma surgery outcome: a meta-analysis. *J Clin Oncol* 2012; 30(20):2559–65.